

Conjunctivitis induced by a red bodied mite, *Neotrombicula autumnalis*

Benjamin J. Parcell^{1,*}, Graeme Sharpe², Brian Jones^{3,4}, and Claire L. Alexander⁴

¹ Department of Microbiology, Ninewells Hospital, Dundee, DD1 9SY, United Kingdom

² Department of Ophthalmology, Ninewells Hospital, Dundee, DD1 9SY, United Kingdom

³ Department of Microbiology, Glasgow Royal Infirmary, Glasgow, G4 0SF, United Kingdom

⁴ Scottish Parasite Diagnostic and Reference Laboratory, Stobhill Hospital, Glasgow, G21 3UW, United Kingdom

Received 7 June 2013, Accepted 26 June 2013, Published online 4 July 2013

Abstract – This is a description of an unusual case of conjunctivitis caused by a trombiculid red mite, *Neotrombicula autumnalis*. The patient's condition improved only after its removal and with application of carbomer gel eye drops. There have been reports of increasing numbers of severe cases of trombiculosis over the last 15 years particularly in Germany and a number of cases have also been reported in the United Kingdom. Cases where trombiculid larvae feed on any region of the head or face of humans are unknown. In addition it is most likely the patient acquired the infection from her pet cat and this is the first description of acquisition from this animal.

Key words: *Neotrombicula autumnalis*, Mite, Conjunctivitis, Trombiculosis, Case report.

Résumé – **Conjonctivite induite par un aoutat, *Neotrombicula autumnalis*.** Ceci est la description d'un cas inhabituel de conjonctivite causée par un acarien Trombiculidae, *Neotrombicula autumnalis*. La condition de la patiente ne s'est améliorée qu'après extirpation de l'animal et application de gouttes pour de gel pour les yeux au carbomer. Un nombre accru de cas sévères de trombiculose a été rapporté ces quinze dernières années d'Allemagne et des cas ont aussi été rapportés du Royaume Uni. Les cas où les aoutats se nourrissent sur une région de la tête ou de la face sont inconnus. De plus, il est très probable que la patiente a acquis l'infection de son chat, et ceci est la première description d'une transmission depuis cet animal.

Introduction

One of the most common red bodied mites in Europe is *Neotrombicula autumnalis* which is known by many names such as the harvest mite, *lepte autumnal* and aoutat [1, 2]. There exist over 1,200 species of trombiculid mite found widely distributed in many countries of which approximately 50 can cause disease in humans or animals. They belong to the family Trombiculidae [1]. Clinical presentations of *Neotrombicula autumnalis* include pruritic dermatitis described as trombiculosis or Scrub itch. Previously, patients were rarely referred for dermatologist review unless symptoms were severe. Over the last 15 years, cases of severe trombiculosis have increased in Western Germany and in the United Kingdom [2, 3].

Case report

A 72-year-old female from Perthshire, Scotland, United Kingdom presented to the Outpatient Ophthalmology Clinic with a two-week history of a painful, gritty, red left eye which failed to improve with a liquid paraffin eye ointment, Lacri-Lube. On examination, her conjunctiva was found to be mildly red and she had normal visual acuity. On close inspection, a live mite was identified in contact with the left upper eyelid margin. The patient's past medical history included left eye cataract surgery twelve weeks prior, not thought to be of significance to her current presentation and from which she had made a full recovery. She reported no history of travel or hill walking, lived independently and kept a pet cat. The mite was photographed and removed without local anaesthetic. Photographic images were sent to the Scottish Parasite Diagnostic and Reference Laboratory, Stobhill Hospital (Figure 1). On examination the mite's mouthparts were attached and inserted into the tissue of the

*Corresponding author: b.parcell@nhs.net

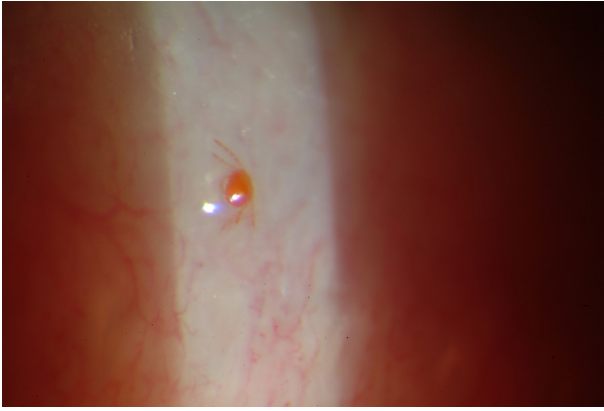


Figure 1. *Neotrombicula autumnalis* mite in contact with the left upper eyelid margin.

host. The mite was identified as the six-legged larva of a red bodied trombiculid red mite, *Neotrombicula autumnalis* which is a common ectoparasite on mammals in the United Kingdom. After removal of the mite, the patient was treated with Carbormer gel eye drops, namely Viscotears, and her symptoms resolved.

Discussion

Mite larvae, also known as chiggers, are most active from May to October [3]. They hatch from eggs in the soil after 10 days and climb onto grass or leaves and are barely visible without magnification. The six-legged larvae may be white to bright red in colour and are 0.25 mm long [1]. It is the larvae that are animal and human ectoparasites and they have a unique way of feeding on human hosts [4]. The larvae do not burrow but tend to attach in clusters [3]. They pierce the skin using sharp mouthparts (chelicerae) and tissue dissolving saliva is injected via a straw-like hollow tube (hypostome) [4]. The larvae usually feed for approximately 2–10 days or longer and then fall to the soil. Here, they develop into eight-legged nymphae then undergo another quiescent phase to become adults [1, 4, 5]. Adult and nymphal mites are soil dwelling predators which feed on other arthropods and their eggs [2]. Feeding can result in a pruritic dermatitis described as trombiculosis presenting with red macules, or wheals with papules 3–6 h after exposure [1]. In severe cases papulovesicles with regional adenitis can occur [3]. Distribution of the lesions depends on the type of clothing worn and area of invasion by the mites [2, 3]. Usually it is the ankles that are affected although any area exposed can result in dermatitis. There have been reports of severe cases of trombiculosis over the last 15 years particularly in Western Germany and in the United Kingdom [2, 3, 6, 7]. Trombiculosis is well recognised in areas where the harvest mite is common and cases are rarely referred to local dermatologists unless severe [3]. Treatment recommendations for trombiculosis are mostly supportive and have included topical agents such as methyl alcohol or camphor [3]. Even common household vinegar (5% acetic acid) has been described in one case as an effective agent to reduce infestations [7]. Gamma benzene hexachloride, oral antihistamines, topical steroids,

vacuuming and washing clothes at 55 °C have been advised [3–5]. As most cases are transmitted when humans or animals come into contact with vegetation or soil that is infested, measures such as wearing protective clothing, avoiding walking through long grass, soaking socks and trouser legs with benzyl benzoate, dimethyl phthalate (DPM) or diethyltoluamide insect repellents (DEET) have also been recommended as ways to prevent infestation. Permethrin repellent has been used in the past however the active ingredient is no longer available for this purpose in the European Union [1, 3].

Trombiculid mites, in particular those of the genus *Leptotrombidium*, are known to be vectors of Tsutsugamushi disease (“scrub typhus”) in the South Pacific, Oceania and Asia [6]. *Neotrombicula autumnalis* larvae were not believed to transmit any infections however, a recent study suggests that they may have the potential to transmit, via transstadial and transovarial routes, the bacterium *Borrelia burgdorferi*, the cause of human Lyme disease [6]. In addition, another recent study has suggested that *Neotrombicula autumnalis* may be a carrier of *Anaplasma phagocytophilum* (formerly *Ehrlichia phagocytophila*) which causes human granulocytic anaplasmosis. This was previously believed to be transmitted by ticks only [5, 8]. Both these infections can cause significant morbidity and fatalities. The numbers of these infections have also increased overall over the last ten years [9,10]. Further studies are needed to demonstrate transmission of these infections to hosts as diagnostic methods and treatment are available.

We believe that the patient acquired the mite from her cat as she had no history of travel, hill walking, gardening or contact with long grass or vegetation. This is an unusual route of infection and only one previous publication has described trombiculosis acquired from close human contact with pet dogs [5]. Disease of the head or face is unknown and this is the first reported case of conjunctivitis caused by a red bodied mite, demonstrating the importance of this differential diagnosis for those living in geographical areas in which the mite is particularly abundant.

Acknowledgements. We would like to thank the patient for allowing us to publish her experience and photograph. We would also like to acknowledge the late Professor Huw Smith for his advice.

References

1. White GB. 2003. Medical acarology and entomology, in Manson’s Tropical Diseases. Cook GC, Zumla A, Editors. Saunders: London, p. 1717–1720.
2. Schöler A, Maier WA, Kampen H. 2006. Multiple environmental factor analysis in habitats of the harvest mite *Neotrombicula autumnalis* (Acari: Trombiculidae) suggests extraordinarily high euryoecious biology. *Experimental and Applied Acarology*, 39, 41–62.
3. Yates VM. 1991. Harvest mites—a present from the Lake District. *Clinical and Experimental Dermatology*, 16, 277–278.
4. Diaz JH. 2010. Mites, including Chiggers, in Principles and Practice of Infectious Diseases. Mandell GL, Bennett JE, Dolin R, Editors. Churchill Livingstone: United States, p. 3643–3647.
5. Guarneri F, Pugliese A, Giudice E, Guarneri C, Giannetto S, Guarneri B. 2005. Trombiculiasis: clinical contribution. *European Journal of Dermatology*, 15, 495–496.

6. Kampen H, Schöler A, Metzen M, Oehme R, Hartelt K, Kimmig P, Maier WA. 2004. *Neotrombicula autumnalis* (Acari, Trombiculidae) as a vector for *Borrelia burgdorferi* sensu lato? Experimental and Applied Acarology, 33, 93–102.
7. Baumann T. 2001. New treatment for harvest mite infestation. Archives of Internal Medicine, 161, 769.
8. Fernández-Soto P, Pérez-Sánchez R, Encinas-Grandes A. 2001. Molecular detection of *Ehrlichia phagocytophilia* genogroup organisms in larvae of *Neotrombicula autumnalis* (Acari: Trombiculidae) captured in Spain. Journal of Parasitology, 87, 1482–1483.
9. Health Protection Scotland. Lyme Disease, Scotland, Annual Totals as at 28 March 2012. <http://www.hps.scot.nhs.uk/giz/lymedisease.aspx> (accessed 7 May 2013)
10. Centers for Disease Control and Prevention. Annual Cases of *Anaplasmosis* in the United States. <http://www.cdc.gov/anaplasmosis/stats/> (accessed 7 May 2013)

Cite this article as: Parcell BJ, Sharpe G, Jones B & Alexander CL: Conjunctivitis induced by a red bodied mite, *Neotrombicula autumnalis*. Parasite, 2013, **20**, 25.



An international open-access, peer-reviewed, online journal publishing high quality papers on all aspects of human and animal parasitology

Reviews, articles and short notes may be submitted. Fields include, but are not limited to: general, medical and veterinary parasitology; morphology, including ultrastructure; parasite systematics, including entomology, acarology, helminthology and protistology, and molecular analyses; molecular biology and biochemistry; immunology of parasitic diseases; host-parasite relationships; ecology and life history of parasites; epidemiology; therapeutics; new diagnostic tools.

All papers in Parasite are published in English. Manuscripts should have a broad interest and must not have been published or submitted elsewhere. No limit is imposed on the length of manuscripts.

Parasite (open-access) continues **Parasite** (print and online editions, 1994-2012) and **Annales de Parasitologie Humaine et Comparée** (1923-1993) and is the official journal of the Société Française de Parasitologie.

Editor-in-Chief:
Jean-Lou Justine, Paris

Submit your manuscript at
<http://parasite.edmgr.com/>